

## LETTER TO THE EDITOR

# Treatment of chronic thrombotic occlusion of the inferior vena cava in a child with cavoportal mesenteric varices

To the Editor: Chronic thrombotic occlusion of the inferior vena cava (IVC) is a rare entity from which 30% of children will go on to develop post-thrombotic syndrome (PTS).<sup>1</sup> Systemic and catheter-directed thrombolysis (CDT) have been utilized with modifications from the adult thrombolysis protocols to decrease the risk of PTS in children.<sup>2,3</sup> When these treatments fail, however, patients are left with few therapeutic options.

We describe a 16-year-old male with lifelong, complete thrombotic occlusion of the IVC despite adequate systemic anticoagulation and attempted CDT resulting in chronic, disabling PTS. His lower extremities were more severely affected than the upper extremities. He was referred to the pediatric interventional radiology (IR) clinic for evaluation and treatment of the IVC occlusion.

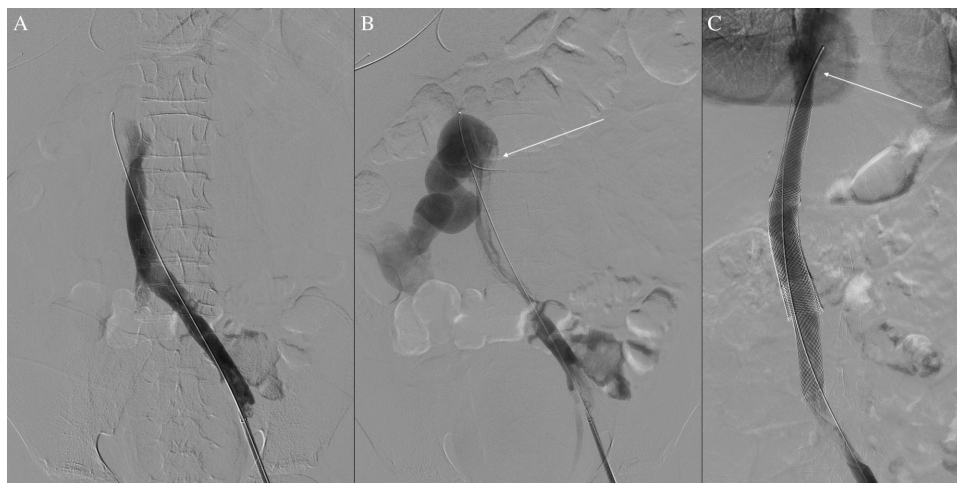
Despite an uncomplicated birth, he presented to his local emergency room at 5 months old with right lower extremity edema and was diagnosed with IVC thrombosis not amenable to surgical intervention and was placed on enoxaparin. An extensive thrombophilia workup was negative. During subsequent admissions for recurrent deep venous thrombosis (DVT), the patient's anticoagulation regimen was escalated, including intermittent intravenous tissue plasminogen activator and multiple sessions of pharmacomechanical thrombolysis coupled with CDT (regimens are outlined in Table S1).

By age 15, his PTS was moderate (modified Villalta score [MVS], 7). Magnetic resonance imaging reconfirmed IVC occlusion with inter-

val development of markedly dilated mesenteric varices draining from the infrarenal IVC into the portal vein. This atypical drainage pattern put the patient at risk of liver damage from portal venous congestion as well as catastrophic intra-abdominal hemorrhage, particularly given his anticoagulation. The development of mesenteric varices coupled with the patient's unremitting PTS symptoms required an attempt at IVC recanalization.

In the IR suite, venography demonstrated complete venous drainage of his bilateral lower extremities and pelvis through direct communication between the infrarenal IVC and the superior mesenteric vein (Figures 1A and 1B). The retrohepatic IVC was patent but ended abruptly above the level of the renal veins. Sharp recanalization was performed with a needle passing from the caudal IVC into a snare device in the more cranial IVC. Intravascular ultrasound was used to image the recanalized IVC and determine the stent/balloon size. Self-expanding stents (Wallstent, Boston Scientific, Marlborough, MA) were deployed and dilated to size with high-pressure angioplasty balloons. The final venogram demonstrated substantial reduction in flow through the mesenteric varices. Given that there was no other path of venous drainage, variceal embolization was deferred with the expectation that reestablishment of flow through the IVC stent complex would preferentially exclude variceal flow.

The patient was admitted and his anticoagulation regimen resumed, and he was discharged 2 days later with a therapeutic heparin assay.



**FIGURE 1** (A) Left femoral vein approach digital subtraction venogram (DSV) showing opacification of the inferior vena cava (IVC), with delayed images (B) demonstrating drainage of the IVC into dilated mesenteric varices (arrow) without normal flow into the right atrium. (C) Postrecanalization DSV demonstrating opacification of the IVC and flow through patent stents into the right atrium (arrow) without any mesenteric collateral flow

At 7 days postdischarge, the patient returned for follow-up stent check. His MVS was 5, improved from 7. Repeat venogram demonstrated complete absence of flow through the mesenteric collaterals with robust laminar flow from the IVC into the right atrium (Figure 1C). At 14 months following recanalization, the patient's MVS was 3 (mild PTS).

PTS is a syndrome of chronic venous insufficiency following DVT, the symptoms of which are thought to be due to venous hypertension resulting from valvular damage.<sup>4</sup> In children, the frequency of PTS following DVT is between 23-28%.<sup>5</sup>

Systemic thrombolysis has been utilized for treatment of pediatric venous thrombosis to decrease the risk of PTS. The incidence and severity of PTS are decreased when venous flow is rapidly restored.<sup>2,3</sup> These studies, however, do not specifically define a patient population for which routine pharmacomechanical CDT should be pursued to prevent PTS.<sup>6-8</sup> It is also unclear when pharmacomechanical CDT should be used rather than systemic anticoagulation; therefore, adult guidelines are modified for pediatric patients.<sup>9</sup>

Our patient had a delayed presentation without long-term effective intervention. Evidence-based guidelines for what appropriate management is in such cases is lacking. In a large series of adults with chronic occlusion of the IVC, 91% reported improvement in pain and 83% in swelling after recanalization.<sup>10</sup> In a smaller series of pediatric patients, stenting was found to be safe and effective, with the primary complication being in-stent restenosis, which could usually be safely recanalized.<sup>11</sup>

In summary, PTS symptoms in the setting of recurrent central venous occlusion refractory to aggressive medical therapy can present a management challenge. The relative rarity of these cases in the pediatric population limits the availability of evidence-based guidelines. When patients fail traditional medical management, symptoms may be improved with central venous recanalization and stenting.

## CONFLICT OF INTEREST

Kavita Patel is a Data and Safety Monitoring Board member at Daiichi Sankyo. All the other authors have no conflict of interest to declare.

## ORCID

Christopher Hesh  <https://orcid.org/0000-0003-2559-7758>

Christopher Hesh<sup>1</sup> 

C. Matthew Hawkins<sup>1,2</sup>

Kavita Patel<sup>3,4</sup>

Anne E. Gill<sup>1,2</sup>

<sup>1</sup>Department of Radiology & Imaging Sciences, Emory University School of Medicine, Atlanta, Georgia

<sup>2</sup>Pediatric Institute, Children's Healthcare of Atlanta, Atlanta, Georgia

<sup>3</sup>Department of Pediatrics, Emory University School of Medicine, Atlanta, Georgia

<sup>4</sup>Aflac Cancer and Blood Disorders Center, Children's Healthcare of Atlanta, Atlanta, Georgia

## Correspondence

Christopher Hesh, Department of Radiology & Imaging Sciences, Emory University School of Medicine, 1364 Clifton Road NE, Suite D112, Atlanta, GA 30322.  
Email: chesh@emory.edu

This case was previously presented at the 2018 meeting of the Society of Interventional Radiology (Los Angeles, CA) on March 18, 2018 where it was awarded first place in the Society of Interventional Radiology Case Competition (<http://rfs.sirweb.org/2018/05/15/treatment-of-chronic-ivc-occlusion-in-a-child-may-2018/>).

## REFERENCES

- Häusler M, Hübner D, Delhaas T, Mühler EG. Long term complications of inferior vena cava thrombosis. *Arch Dis Child.* 2001;85:228-233.
- Wang M, Hays T, Balasa V, et al. Low-dose tissue plasminogen activator thrombolysis in children. *J Pediatr Hematol Oncol.* 2003;25:379-386.
- Manco-Johnson MJ, Nuss R, Hays T, Krupski W, Drose J, Manco-Johnson ML. Combined thrombolytic and anticoagulant therapy for venous thrombosis in children. *J Pediatr.* 2000;136:446-453.
- Kahn SR, Ginsberg JS. The post-thrombotic syndrome: current knowledge, controversies, and directions for future research. *Blood Rev.* 2002;16:155-165.
- Goldenberg NA, Donadini MP, Kahn SR, et al. Post-thrombotic syndrome in children: a systematic review of frequency of occurrence, validity of outcome measures, and prognostic factors. *Haematologica.* 2010;95:1952-1959.
- Watson L, Broderick C, Armon MP. Thrombolysis for acute deep vein thrombosis. *Cochrane Database Syst Rev.* 2014;(1):CD002783.
- Goldenberg NA, Durham JD, Knapp-Clevenger R, Manco-Johnson MJ. A thrombolytic regimen for high-risk deep venous thrombosis may substantially reduce the risk of postthrombotic syndrome in children. *Blood.* 2007;110:45-53.
- Goldenberg NA, Branchford B, Wang M, Ray C, Durham JD, Manco-Johnson MJ. Percutaneous mechanical and pharmacomechanical thrombolysis for occlusive deep vein thrombosis of the proximal limb in adolescent subjects: findings from an institution-based prospective inception cohort study of pediatric venous thromboembolism. *J Vasc Interv Radiol.* 2011;22:121-132.
- Vedantham S, Goldhaber SZ, Julian JA, et al. Pharmacomechanical catheter-directed thrombolysis for deep-vein thrombosis. *N Engl J Med.* 2017;377:2240-2252.
- Murphy EH, Johns B, Varney E, Raju S. Endovascular management of chronic total occlusions of the inferior vena cava and iliac veins. *J Vasc Surg Venous Lymphat Disord.* 2017;5:47-59.
- Frazer JR, Ing FF. Stenting of stenotic or occluded iliofemoral veins, superior and inferior vena cavae in children with congenital heart disease: acute results and intermediate follow up. *Catheter Cardiovasc Interv.* 2009;73:181-188.

## SUPPORTING INFORMATION

Additional supporting information may be found online in the Supporting Information section at the end of the article.